

STUDY OF SUPRA ORBITAL NOTCHES & FORAMINA IN UNKNOWN DRY HUMAN SKULLS

Arun Kumar S. Bilodi¹, Linda J. B², Kunjomon P. C³, Sarath Babu K⁴

¹Professor, Department of Anatomy, Sree Mookambika Institute of Medical Sciences, Kulasekaram, Kanyakumari, Tamilnadu.

²Assistant Professor, Department of Anatomy, Sree Mookambika Institute of Medical Sciences, Kulasekaram, Kanyakumari, Tamilnadu.

³Professor & HOD, Department of Anatomy, Sree Mookambika Institute of Medical Sciences, Kulasekaram, Kanyakumari, Tamilnadu.

⁴Statistician, Department of Anatomy, Sree Mookambika Institute of Medical Sciences, Kulasekaram, Kanyakumari, Tamilnadu.

ABSTRACT

AIM OF THE STUDY

The objective of the present study is to know the variations in the combinations and numbers of the notches and foramina of the unknown adult skulls. This study also gives the positions of supra orbital notch and the foramina in the frontal region which is a very important in the surgical procedures of eyebrow like ptosis.

PLACE OF THE STUDY

Study was done in the department of Anatomy at Sree Mookambika Institute of Medical Sciences and Sree Mookambika Institute of Dental Sciences, in Kulasekaram, of Kanyakumari district, Tamilnadu, INDIA.

PERIOD OF STUDY

This study was done in the year 2015.

MATERIALS AND METHODS

Twenty five dry unknown human skull from the Department of Anatomy at Sree Mookambika Institute of Medical Sciences and twenty six from the department of Anatomy of Sree Mookambika Institute of Dental sciences constituted the materials for the present study. Each skull was examined for the presence of various types and positions of supra orbital notches and foramina. Their number presence or absence and size were noted. Other associated variations were also observed. The vertical and transverse diameters of the orbits were measured with the help of sliding calipers. The distances of notches and foramina were also measured from the midline of the skull near glabella.

RESULTS AND OBSERVATION

The results of the present study were as follows.

RESULTS OF THE PRESENT STUDY AT SREE MOOKAMBIKA INSTITUTE OF MEDICAL SCIENCES, IS AS FOLLOWS

The percentage of supra orbital notches on the right side was 76% and on left side was 52%. While supra orbital foramina on the right side was 52% and on left side was 68%. Multiple supra orbital foramina were absent on right side and 9% on left side. The incidences of combinations with incomplete supra orbital foramina on the left side was 4.5% but they were absent on the right side.

RESULTS OF THE PRESENT STUDY AT SREE MOOKAMBIKA INSTITUTE OF DENTAL SCIENCES AS FOLLOWS

Skulls showed the presence of 73.07% supra orbital notches, on right side and 62% on the left side. Similarly incidences of supra orbital foramina were 53.84% on the right side and 65.38% on the left side. Unlike in the studies at Medical Sciences, three skulls (12.5%) showed multiple supra orbital foramina on right side and two skulls (8.3%) on the left side. No skull showed combination with incomplete supra orbital foramina, but one skull showed absence of supra orbital foramina and notches on the right side only.

DISCUSSION

The present study on supraorbital notches and foramina has been well compared and correlated with available literature by various workers.

CONCLUSION

This study is of paramount clinical importance for anaesthetists, dentists, plastic surgeons and faciomaxillary surgeons. Hence it has been studied and reported.

KEYWORDS

Human skull, supra orbital foramina and notches, incomplete foramina, absence of foramina and notches.

Submission 29-10-2015, Peer Review 30-10-2015,

Acceptance 07-12-2015, Published 22-12-2015.

Corresponding Author:

Dr. Arun Kumar S. Bilodi,

C/o. Sree Mookambika Institute of Medical Sciences,
Kulasekaram, K. K. District, Tamilnadu.

E-mail: drbilodi@yahoo.com

DOI: 10.18410/jebmh/2015/1263

HOW TO CITE THIS ARTICLE: Bilodi AKS, Linda JB, Kunjomon PC et al. Study of supra orbital notches & foramina in unknown dry human skulls. J Evid Based Med Healthc 2015; 2(59), 8940-45. DOI: 10.18410/jebmh/2015/1263

INTRODUCTION: Supra orbital margin of the orbit bears notches as supra orbital notches which are present at the junction of medial one third and lateral two thirds. Sometimes ligaments bridges across the supra orbital notches and gets ossified converting them into Supra orbital foramina. (Jack. T. Stern).^[1] It has been named as Supraorbital ligament by Duke Elder.^[2] (Duke Elder) Schaffer has claimed that this supra orbital ligament converts supra orbital notches into foramina^[3] [Schaffer]. Supra orbital vessels and nerves pass through these notches and foramina, they supply eye lids & conjunctiva by terminal branches.^[4] [Gary's Anatomy]. The occurrence of multiple notches or foramina has been mentioned by Webster et al.^[5] [Webster]. Other workers like Berry 1975,^[6] Kimmara 1977^[7] Gumusburan et al 2002^[8] also done a study on supraorbital notches and foramina.

MATERIALS AND METHOD: Fifty one dry unknown human skulls were collected from Sree Mookambika institute of medical sciences and Sree Mookambika Institute of Dental Sciences, Kulasekaram, Kanyakumari district, Tamilnadu. The skulls of the articulated skeleton kept in demonstration halls were also included for the present study. No foetal skull was studied.

Out of fifty one unknown dry human skulls, twenty five skulls were from Sree Mookambika Institute of medical sciences and twenty six from Sree Mookambika institute of dental sciences. This study was made on supraorbital notches, supraorbital foramina, incomplete foramina, and on absence of notches and foramina on both sides. Their variations in the size and numbers were noted and their percentages of incidences were calculated and tabulated in the table form. Distance of notches and foramina were also measured from the midline of skull (near the glabella). The vertical and transverse diameters of the orbits were also measured. The results were tabulated in the given tabular column. & statistical importance were calculated.

OBSERVATIONS:

In each skull following observations were made:

- i. Presence of supra orbital notches, or supra orbital foramina,
- ii. Presence of both notches and foramina.
- iii. Their absence either unilaterally or bilaterally.
- iv. The vertical and transverse diameters of the orbits.
- v. Distance of supra orbital foramina or supraorbital notches from the mid line.
- vi. Associated findings were also observed and noted.

Then findings were tabulated in different table which are given below.

	Right		Left	
	Number	(%)	Number	(%)
Supra Orbital Notches	16	64.00	8	32.00
Supra Orbital Foramina	9	36.00	14	56.00
Multiple Supra Orbital Foramina	0	0	2	08.00
Combination with in complete supra orbital foramen	0	0	1	04.00
Absence of Supra Orbital Foramina and Supra Orbital Notches	0	0	0	0
Total	25	100	25	100

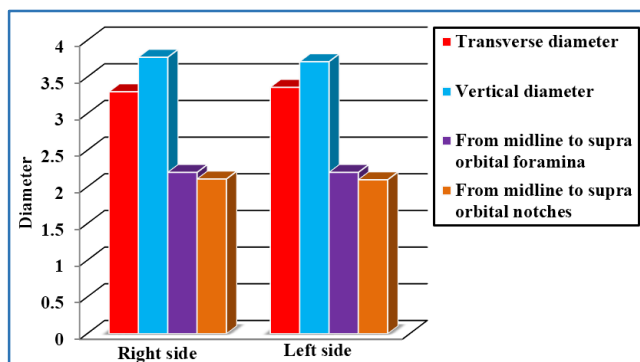
Table 1: Percentages of supra orbital notches and supra orbital foramina at Sree Mookambika Institute of Medical Sciences

	Right		Left	
	Number	(%)	Number	(%)
Supra Orbital Notches	13	50.00	11	42.31
Supra Orbital Foramina	9	34.62	13	50.00
Double/multiple Supra Orbital Foramina	3	11.54	2	7.69
Combination with in complete supra orbital foramen	0	0	0	0
Absence of Supra Orbital Foramina and Supra Orbital Notches	1	3.84	0	0
Total	26	100	26	100

Table 2: Percentages of supra orbital notches and supra orbital foramina at Sree Mookambika Institute of Dental Sciences

	Right side (MEAN±SD)	Left side (MEAN±SD)
Transverse diameter	3.30±4.34	3.36±2.67
Vertical diameter	3.77±2.56	3.71±3.25
From midline to supra orbital foramina	2.20±8.34	2.20±4.04
From midline to supra orbital notches	2.11±2.12	2.10±2.19

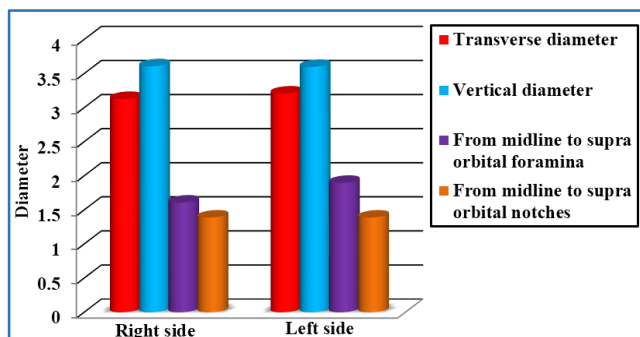
Table 3: Average of vertical and transverse diameters by measurement of supra orbital foramina from midline and measurement of Supra orbital notches from midline at Sree Mookambika Institute of Medical Sciences



Graph 1: Average of vertical and transverse diameters by, measurement of Supra Orbital Foramina from midline and measurement of Supra Orbital Notches from midline at Sree Mookambika Institute of Medical Sciences

	Right side (Mean±SD)	Left side (Mean±SD)
Transverse diameter	3.13±1.56	3.21±2.15
Vertical diameter	3.61±2.67	3.60±3.78
From midline to Supra Orbital Foramina	1.61±3.56	1.90±2.56
From midline to Supra Orbital Notches	1.39±2.56	1.39±1.09

Table 4: Average of vertical and transverse diameters by, measurement of Supra Orbital Foramina from midline and measurement of Supra Orbital Notches from midline at Sree Mookambika Institute of Dental Sciences



Graph 2: Average of vertical and transverse diameters by, measurement of supra orbital foramina from midline and measurement of supra orbital notches from midline at Sree Mookambika Institute of Dental Sciences

Supraorbital notches and Supra orbital foramina from the mid line	Right	Left
Singh et al	24.64+3.35MM	24.88+2.63MM
Ilayperuma et al	25.42+-2.49mm	24.64+-3.16mm
Trivedi	24.30mm	23.73mm
Nidhi Sharma	21.94+-0.32	20.11+-0.73mm

Table 5: Showing the incidences of supraorbital notches and supra orbital Foramina both on right and left side as studied by different authors

STATISTICAL ANALYSIS: From the above measurements, mean and standard deviation, median, range, and mode were calculated. Data analysis was done using Statistical package for social sciences (spss)^[9] version and p<0.05 was considered statistically significant.

DISCUSSION: Supra orbital notches are present at the junction of lateral two third and medial one third of the orbit. Supra orbital foramina are formed by the ossification of periosteal ligament.^[10] (Henry Hollinshed) The incomplete foramina is formed by partial ossification of the same ligament creating a slight gap at its lower margin.^[11] (Last RJ)

A. Incidence of supra orbital foramina:

- i. Duke Elder (1961) and Hollinshed (1966)-25%
- ii. Rao et al (1997) -6.5% in south Indian skulls.^[12]
- iii. Arun Kumar S Bilodi, and Sandikop M.B.(2002), in their studies showed 39% on the right side and 43.3% on the left side.^[13] (Bilodi)
- iv. Sinha DN (1978) study showed 34.25% on the right side and 28.5% on the left side.^[14](Sinha)
- v. Londhe et al (2011) study showed 30.7% on the right side and 18.81% on the left side.^[15]

B. Incidence of supra orbital notches:

- i. Study of Sinha DN (1978) showed 14.2% on the right side and 25.55 on the left side.^[14]
- ii. Rao et al [1997] on supra orbital notches studies showed 38.5% in adult skull. Sides are not mentioned.
- iii. Arun Kumar S Bilodi and Sanikop MB (2002) in their study showed 47.38% on the right side and 36.6% on left side. ^[13]
- iv. Study of Londhe et al (2011) showed 39.6% on the right side and 47.52% on the left side. In their studies incidences of foetal skull showed presence of supraorbital notches 71.18% on the right side and 66.10% on the left side. (Londhe et al)^[15]

Incidence of incomplete Foramina: Studies of Londhe et al in adult skull showed 29.7% on right side and 39.66% on left side, while in foetal skulls, 18.64% on the right side and 15.25% on left side.

Incidence of complete absence of both notches and foramina in adult skulls were not seen in Londhe et al studies. Studies of foetal skull by same author showed 10.16% on right side and 18.64% on left side. But incidences of complete absences of notches and foramina were not there in adult skulls.

Present study showed no incidences of complete absence of foramina and notches on both sides.

Chavan W M and Shende M R (2013) did the study on foramina and notches in 96 adult human skulls, their study showed presence of supraorbital foramina was 59.37% in male and 40.62% in female. ^[16]

Out of 57 male skulls, notches were present on both sides in 52.60% while notches were present one side and foramina in other side in 36.9%, the remaining 39 female skull showed 30.8% notches bilaterally while 38.5% skull showed notches one side and foramina on other side. out of 36.9% male skulls 31.6% skull shows notches on right side and 5.3% foramina on right side, while 18.3% skull showed notch on left side and 85.6% foramina on left side. Out of 38.55% human skull only 7.7% showed notches on right side and 30.8% foramina in left side. Their study showed presence of accessory foramina in male skulls. Out of them 10.5% were present on right side and 21% were present on the left side. The male skull showed accessory foramina on both sides in 50.7% while in 7.7% in female skulls. In their study all accessory foramina were present on left side in female skulls but there were no accessory foramina on the right side in female skulls.^[16] (Chavan and Shen)

It has been believed through hypothesis that incidence of supraorbital notches were greater in the population of warm region when compared to cold region. This hypothesis is related to thermoregulated process in the region of supraorbital region.^[17] (Tomaszewska et al 2013)

Nishtha et al (2014) conducted morphological study on supraorbital notches and foramina in North Indian human skulls in 71 adult North Indian dried human skulls of unknown age and gender in the Department of Anatomy at Motilal Nehru Medical college, Allahabad, India in association with Rohilkhand Medical college and Hospital, Bareilly and Institute of Dental Sciences Bareilly, India. Their study showed supra orbital foramina in 27 orbits out of then 8 were seen on both sides, 3 on left side and 8 on right side with overall incidences of 19.01%. Bilateral supraorbital foramina was present only in 11.27% only. while unilateral in 7.75% (on the right side 5.63%, and on the left side 2.11%).^[18] The incidences of supraorbital notches of the above same authors were present in 115 orbits. (they were present on both sides and 8 on left side and 3 on right side) The overall incidences of the notches were 80.99% where as they were present on both sides 72.4% while supra orbital notches were present unilaterally in 2.11% on right side and in 5.63% on left side.^[18]

Berry and Berry (1967), Dodo (1980, 1987), Hauser and De Stefano (1989) and Hanihara (2001) did large-scale analyses of discrete traits to assess interpopulation relationships. Dodo (1974) and Hauser and De Stefano (1989) classified the discrete human cranium into three categories, they were vessels and nerve variation, hyperstatic variation and hypostatic variation.

Our present study: At Sree Mookambika Institute of Medical sciences showed following results:

a) Percentages of supraorbital foramina was higher on left side (68%) than on the right side (32%), while percentage of supraorbital notches were higher on right side (76%) than on the left side (48%). Percentage of multiple supraorbital foramina were seen only in two skulls (9%) on the left side but none on right side. There was only one skull which showed incomplete foramina

on the left side (4.5%) only. In our study no skull showed absence of foramina and notches.

So from the above study, it is observed that our study is not similar to Rao et al (1997), and Londhe et al studies (2011) where there were higher incidences of supraorbital foramina on right side than on the left side, and their study goes in favour of previous study of Bilodi et al [2002]. Berry[1975] had found equal incidence on supra-orbital foramina in the study on Mexican skulls. Study on Supraorbital notches showed similarity with that of previous study of Bilodi et al. [2002], But it is not in favour of study of Sinha. B. N [1978] Our present study showed no incidence of complete absence of foramina and notches on both sides. No study has been done on foetal skull.

Study at Sree Mookambika Institute of Dental Science showed the following results:

b) Percentage of supraorbital foramina was higher on the left side (65.38%) than on right side (34.62%). The Percentage of supraorbital notches were higher on the right side (73.07%) than on the left side (26.63%). There were also skulls showing multiple supraorbital foramina on both sides (12.5%) (On the right side) There were no skulls showing supraorbital foramina on both sides while there was one skull which showed absence of foramina on the right side. (4.1%). Our study goes in favour of study of Arun kumar S Bilodi and Sanikom M B where this study showed higher on left side (43%) than on the right side (39%) and B. N. Sinha studies -34.25% on the right side and 43.3% on the left side. Berry had found equal incidence on supra-orbital foramina in Mexican crania. But in our studies no skulls showed equal incidences unlike that of Berry studies [1975].

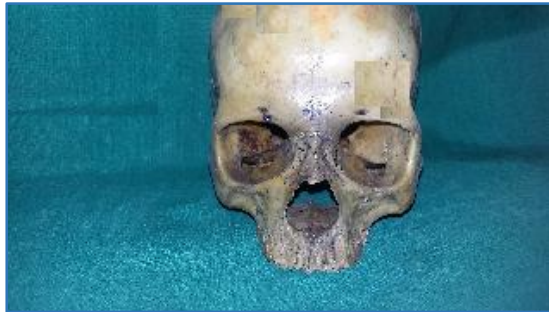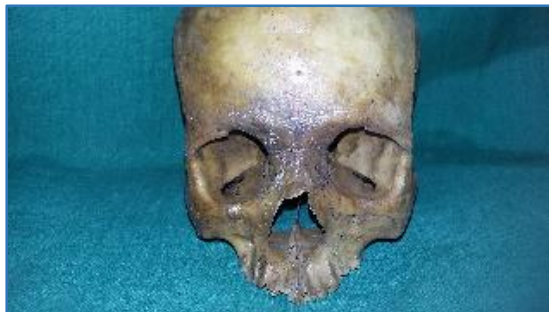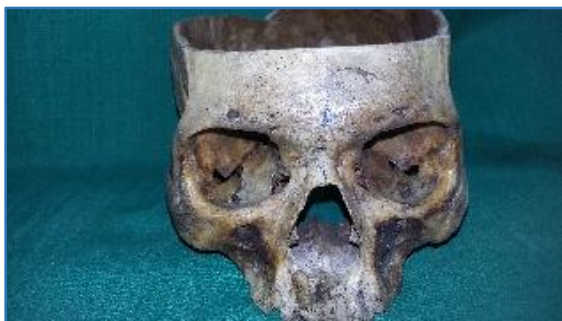In addition to this findings we also measured horizontal and vertical diameter of both orbits and also measured the distance of foramina and notches from the point on the glabella and anterior median plane at our medical as well as dental colleges.

At Sree Mookambika Institute of Medical Sciences:

- I. The average transverse diameter of the orbit on the right side was 3.772cm on the right side and 3.71cm on the left side.
- II. The average vertical diameter of the orbit on the right side were 3.304 cm on the right side and 3.36 cm on the left side.
- III. The average distances of supraorbital foramina from the midline were 2.208cm on the right side and 2.204cm on the left side.
- IV. The average distances of supraorbital notches from the midline were 2.112cm on the right side and 2.1cm on the left side.

At Sree Mookambika institute of dental sciences:

- i. The average transverse diameter of the orbit on the right side was 3.138cm on the right side and 3.603cm on the left side.
- ii. The average vertical diameter of the orbit on the right side were 3.138 cm on the right side and 3.219 cm on the left side.
- iii. The average distances of supraorbital foramina from the midline were 1.611cm on the right side and 1.903cm on the left side.
- iv. The average distances of supraorbital notches from the midline were 1.396cm on the right side and 1.396 cm on the left side.

**Fig. 1****Fig. 2****Fig. 3**

CONCLUSION: The supraorbital notches and foramina as important anatomical landmark during surgical procedures, invasive procedures for oral and maxillofacial surgery. Supraorbital nerve block are commonly carried out in the region of supraorbital foramina during closure of facial wound biopsy, debridement. Hence this study is of surgical importance.

CARRY HOME MESSAGE: The knowledge of supra orbital notches and foramina will be of great importance in cases of injuries on supraorbital neurovascular bundles in the surgeries of forehead regions as well as eyelids. So every surgeon should have perfect knowledge of Supra orbital notches and foramina and their variations.

ACKNOWLEDGEMENT: we sincerely thank the Director and the Chairman of the Sree Mookambika Educational Trust for permitting us to use the study materials that is present in the Department of Anatomy of our esteemed institutions.

REFERENCES:

1. Jack T Stern. Essentials of gross Anatomy, Editon 1, Jappy Brothers, New Delhi 1990;487.
2. Duke Elder SS. System of Ophthalmology, 1st edition. Henry Kimpton; London 1961;Volume(II):401.
3. Schaeffer JP. Morn's Human Anatomy, 11th Ed., New York; Toronto & London; McGraw Hill Book company, INC 1953;119-147.
4. Grays anatomy, 39th Edition, page 513-517.
5. Webster RC, Gaunt JM, Hamden US, et al. Supraorbital & supratrochlear notches & foramina, Anatomical variations & surgical relevance Laryngoscope, March 1986;96(3):311-315.
6. Berry AC. Factors affecting incidence of nonmetrical skeletal varients, Journal of Anatomy (1975), 120, page No 519-535. Quoted in International J. of Healthcare & Biomedical Research 2013;(4):279-283.
7. Kimura K. Foramina and notches on supraorbital margin in some racial groups, Acta Anat Nipponica 1977;52:203-209.
8. Gumusburun E, Katkici U, Eradil H, et al. Variations of supraorbital traits Morphologie Mar 2002;86(272):19-22.
9. Hauser G, De Stefano GF. Epigenetic variants of the Human Skull.Ed.Schweizerbart, Stuttgart 1989.
10. Henery Hollinshed W. Anatomy for Surgeons; Vol-IP, III, New York & London, Hoeber Harper 1966;111-114.
11. Last RJ. in:Eugene wolfs Anatomy of the Eye & orbit 6th Ed.London: H. K. Lewis & Co. Ltd, 1968;p23.
12. Rao et al. Study of supra orbital Notch and Foramen in 200 Human skulls in south India, Anatomical Adjuncts: 1997;3(2):15-22.
13. Bilodi Arun Kumar S, Sanikop MB. Some observations on supra orbital foramina in Human skulls in Karnataka, Anatomica Karnataka, 2002;1(3):17-23.
14. Sinha DN. Study of supra orbital notch and foramen in North Indian Human Skulls, J Anat Soc India, 1978;27:124-126.
15. Londhe SR, Jadhav AS, Gosavi AG. Study of Supra Orbital Notch and Foramen in Adult and Foetal Human Skull. Al Ameen J Med Sci 2011;4(4):386-390.
16. Chavan WM, Shende MR. The study of supraorbital notches and foramina in adult skulls. International J of Healthcare & Biomedical Research July 2013;1(4):279-283.

17. Tomaszewska A, Tomczyk J, Kwiatkowska B. Characterisation of the supraorbital foramen and notch as an exit route for the supraorbital nerve in populations from different climate conditions. *Homo* 2013;64:58-70.
18. Nishtha Singh Alok K, Singh, Rakesh Gupta, et al. A study of the supraorbital notch and foramen in north Indian human crania. *Eur. J. Anat.* 2014;18(1):21-25.