

A Comprehensive Study on Reducing Radiation and Contrast in Protocol- CT Aortography

Anubhav Mohan Bhardwaj¹, Dr Ashish Kumar Shukla², Abhishek Kaushik³,
Arif Hussain Malla⁴, Gayatri gusain⁵
^{1,2,3,4,5}*Santosh deemed to be university*

Abstract—Background: Computed Tomography Aortography (CTA) is indispensable for evaluating aortic pathologies such as aneurysms and dissections. However, conventional protocols require high radiation exposure and large volumes of iodinated contrast, posing risks of cancer and contrast-induced nephropathy. Optimized low-dose and low-contrast strategies supported by iterative reconstruction may mitigate these risks.

I. INTRODUCTION

CT Aortography is a vital imaging technique that plays a central role in the diagnosis and management of aortic diseases, such as aortic aneurysms, dissections, and stenosis. These conditions can lead to life-threatening consequences if not diagnosed and treated promptly. As such, CT Aortography provides critical information to guide clinical decisions, particularly in surgical planning or in the monitoring of disease progression. The high-resolution imaging of the aorta and its branches is indispensable in providing the necessary diagnostic data, allowing healthcare providers to make informed decisions in a timely manner.

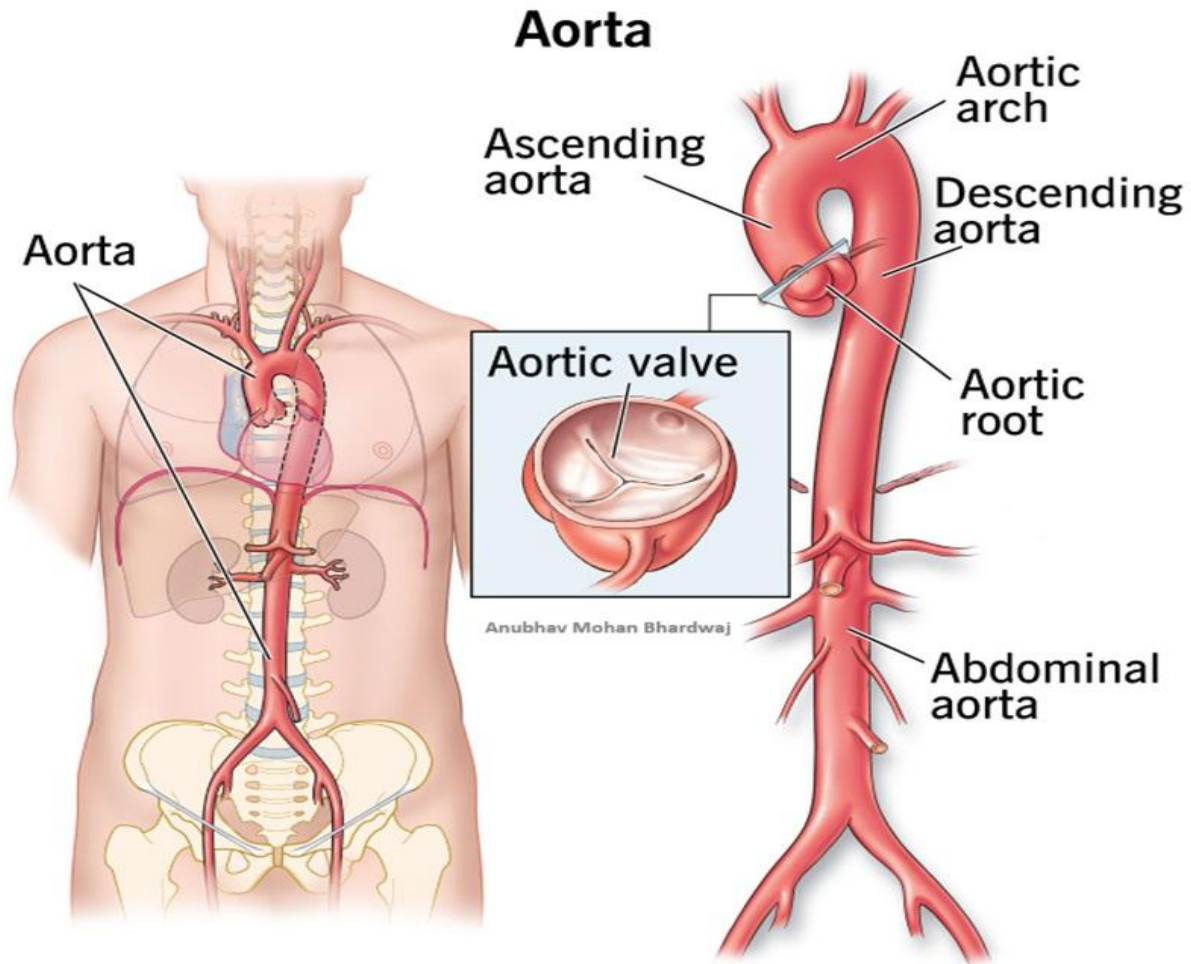
Traditionally, CT Aortography requires high doses of ionizing radiation and substantial amounts of contrast media, both of which carry significant risks to patients. Radiation exposure in CT imaging is a well-documented concern, with cumulative exposure linked to an increased risk of cancer, particularly in individuals who require repeated imaging over the course of their lives. This issue is particularly critical for patients with chronic conditions, such as those with aortic diseases, who may require multiple imaging

exams throughout their treatment and monitoring processes.

Similarly, the use of iodinated contrast agents in CT Aortography has raised concerns, especially for patients with pre-existing renal conditions or those at risk of contrast-induced nephropathy. The potential for adverse reactions to contrast media, including kidney damage, allergic responses, and other complications, makes it imperative to minimize contrast usage while maintaining diagnostic efficacy. Despite the known risks, reducing radiation and contrast in CT imaging without compromising image quality and diagnostic accuracy remains a significant challenge. The reduction of radiation dose and contrast medium usage in CT aortography is a matter of significant clinical importance. With patient safety now a central focus and the long-term health risks of radiation more widely acknowledged, the need for optimization has intensified, there is a pressing need for imaging protocols that can strike a balance between minimizing risks and providing high-quality diagnostic results. This study, focusing on the Siemens Somatom Go Now 128 Slice CT scanner, aims to explore how the latest advancements in technology can address this challenge.

Anatomy of the Aorta:

The aorta, the largest artery in the human body, transports oxygenated blood from the left ventricle to systemic circulation. Shaped like a cane, it rises briefly from the heart, arches over, and then travels through the chest and abdomen before dividing into the arteries that supply the pelvis and lower limbs. Along its course, multiple branches ensure blood reaches vital organs, muscles, and tissues.



- **Ascending Aorta:** The initial portion of the aorta emerging from the heart, giving off the coronary arteries that supply oxygenated blood to cardiac tissue.
- **Aortic Arch:** Forms a curve above the heart and gives rise to three primary branches—the brachiocephalic, left common carotid, and left subclavian arteries—which supply the head, neck, and upper extremities.
- **Descending Aorta:** Divided into thoracic and abdominal segments. The thoracic portion supplies the chest wall, lungs, and esophagus, while the abdominal portion gives rise to key arteries such as the celiac trunk, mesenteric arteries, renal arteries, and gonadal arteries, supporting the digestive system, kidneys, and reproductive organs.
- **Aortic Bifurcation:** The aorta bifurcates into the right and left common iliac arteries at the level of

the fourth lumbar vertebra, which serve the pelvis and lower limbs.

Technological Developments in CT Imaging: Advances in CT imaging technology in recent years have had a profound impact on the field, providing opportunities to reduce both radiation exposure and contrast usage while preserving or even enhancing image quality. One such development is the introduction of the Siemens Somatom Go Now 128 Slice CT scanner, which boasts state-of-the-art features designed to optimize imaging procedures for safety and efficiency. With its low-dose imaging capabilities, this scanner has the potential to significantly reduce radiation exposure during CT Aortography without sacrificing diagnostic accuracy. The Somatom Go Now 128 Slice CT scanner uses advanced algorithms and reconstruction techniques that enhance the quality of images while reducing the

amount of radiation required for diagnostic clarity. These innovations are critical in addressing the growing concerns regarding radiation safety, particularly in vulnerable populations who are more sensitive to radiation exposure. The capacity of the scanner to generate high-resolution images at reduced radiation doses enables clinicians to make accurate diagnoses with minimal risk to patients. Furthermore, the Siemens system incorporates various imaging protocols designed to optimize contrast media usage. By reducing the volume of contrast needed for high-quality imaging, the scanner can potentially lower the risks of contrast-related adverse effects. These developments offer the possibility of enhancing patient safety while still providing the detailed information necessary for the diagnosis of aortic diseases.

Challenges in CT Aortography

Despite the significant improvements in CT technology, the challenges associated with radiation exposure and contrast usage in CT Aortography persist. One of the primary concerns is the inherent trade-off between reducing radiation dose and maintaining image quality. In clinical practice, there is often a delicate balance that needs to be struck between these two factors. While reducing radiation exposure is essential, it is equally important to ensure that the resulting images retain sufficient resolution and clarity for accurate diagnosis. Similarly, the use of contrast agents presents a challenge. While contrast media are essential for enhancing the visibility of blood vessels and tissue structures, excessive use can lead to serious health complications, particularly for patients with underlying kidney conditions. Additionally, some patients may experience allergic reactions to contrast agents, further complicating the issue. The conventional approach to CT Aortography has been to use the highest possible radiation doses and contrast volumes to ensure the clearest possible images. However, this approach is becoming increasingly untenable in light of the growing awareness of the risks associated with these practices. As a result, there is a pressing need to develop imaging protocols that can deliver high-quality diagnostic images with significantly a reduction in both radiation

dose and contrast requirements, without sacrificing diagnostic reliability.

Health & Radiation dose Risks:

The health risks associated with excessive radiation exposure are well-established in the medical literature. Chronic exposure to ionizing radiation can induce harmful effects at the cellular level, increasing the risk of cancer and other radiation-related illnesses. This is specifically concerning for patients who require repeated imaging procedures over time, such as those undergoing monitoring for chronic conditions like aortic aneurysms or stenosis. The risk of contrast-induced nephropathy is another significant concern with particular relevance for those suffering from pre-existing renal dysfunction. Contrast agents, particularly iodinated contrast, can overwhelm the kidneys' ability to filter and excrete the substance, leading to renal damage or failure. This risk is particularly pronounced in patients with diabetes, hypertension, or pre-existing kidney disease, who are more vulnerable to the adverse effects of contrast media.

The reduction of radiation and contrast agents in CT Aortography is not merely a matter of improving patient comfort or convenience—it is a critical step in minimizing the risks associated with these imaging techniques. The development of protocols that can achieve high-quality imaging while reducing exposure to radiation and contrast agents hold promise for improving clinical outcomes and advancing the safety profile of diagnostic procedures.

Need for Optimized Protocols:

As the medical community becomes increasingly aware of the risks associated with high doses of radiation and excessive contrast usage, there is a growing need for optimized CT Aortography protocols. The goal is to minimize the amount of radiation and contrast agents used during the procedure while still obtaining high-resolution images that provide the necessary diagnostic information.

Optimized imaging protocols are particularly important for patients with chronic conditions that require frequent imaging or those who may be at a high possibility of showing complications related to radiation exposure or contrast media. For example, elderly patients, patients with pre-existing kidney

disease, or those requiring long-term monitoring for aortic conditions are particularly vulnerable to the adverse effects of radiation and contrast agents. By developing protocols that reduce these risks, clinicians can provide safer, more effective care for these patients.

Rationale for the Study:

The reduction of radiation exposure and contrast media is a critical aspect of modern medical imaging. As concerns about patient safety continue to grow, it is essential to find ways to reduce the risks associated with CT Aortography, particularly in patients who require frequent imaging. This study will contribute valuable insights into how technological advancements in CT imaging can be leveraged to improve patient safety and enhance the overall quality of care. Furthermore, the findings of this study could help inform future clinical practices and lead to the development of standardized, optimized protocols for CT Aortography that balance diagnostic accuracy with patient safety. By identifying the most effective ways to reduce radiation and contrast usage, this study has the caliber to improve the long-term outcomes for patients undergoing CT Aortography and set a new standard for imaging protocols in this field.

II. AIM AND OBJECTIVES

Aim of the Study:

To comprehensively evaluate and compare optimized CT Aortography protocols that minimize radiation exposure and contrast media usage, without compromising the diagnostic accuracy required for the assessment of aortic pathologies.

Objectives of the Study:

1. **Radiation Reduction:** To compare radiation exposure between conventional and optimized CTA protocols using the Siemens Somatom Go Now 128-slice CT scanner, and determine whether dose reduction preserves image quality.
2. **Contrast Media Optimization:** To evaluate whether reduced contrast volumes maintain sufficient clarity for the detection of aortic anomalies such as aneurysms and stenosis.
3. **Diagnostic Accuracy:** To assess whether images from optimized protocols remain comparable in accuracy to those produced by traditional techniques.

4. **Patient Safety:** To analyze the potential reduction in risks of CI-AKI and long-term radiation-related effects when using optimized protocols.
5. **Clinical Feasibility:** To examine workflow efficiency, cost-effectiveness, and overall practicality of implementing optimized protocols in routine practice.
6. **Standardization Potential:** To explore the possibility of adopting these optimized protocols across institutions for safer and more uniform CTA practices.

Need of the Study:

CT Aortography (CTA) is a crucial imaging modality for detecting and managing aortic diseases such as aneurysms, dissections, and stenosis. Conventional CTA protocols, however, rely on relatively high radiation doses and large amounts of iodinated contrast media. While these ensure excellent diagnostic images, they expose patients to risks such as radiation-induced malignancies and CI-AKI, especially in those with renal insufficiency. With the growing number of high-risk patients undergoing vascular imaging, there is a pressing need to refine CTA protocols to balance diagnostic precision with patient safety. Recent technological advances—including low kVp techniques, iterative reconstruction algorithms, and ultra-low contrast protocols—have shown promise in reducing both radiation and contrast requirements. Still, further validation is required to establish their clinical effectiveness and feasibility for routine practice.

This study focuses on the Siemens Somatom Go Now 128-slice CT scanner, a modern imaging system with advanced low-dose capabilities. By systematically investigating optimized CTA protocols on this platform, the study aims to evaluate whether significant reductions in radiation and contrast can be achieved while maintaining diagnostic accuracy. Overall, their findings emphasized that combining low kVp settings with modern reconstruction algorithms provides a feasible strategy to substantially reduce radiation dose while preserving high-quality images. This contribution is important in the broader context of radiation safety and aligns with the ALARA principle, advancing safer imaging practices in routine clinical settings.

III. METHODOLOGY

Study Place:

The study was conducted at Santosh Medical & Dental Hospital, Ghaziabad, Delhi NCR.

Design of Study:

Patient Demographics by Protocol

Group	Number of Patients (n)	Gender Distribution (M/F)	Age Range (years)
Standard Protocol	11	6 / 5	25 – 70
Optimized Protocol	11	6 / 5	28 – 62

Total sample size = 22

Inclusion Criteria:

- Adults aged 18–70 years
- Clinically referred for CT Aortography
- Suspected aortic pathology (aneurysm, dissection, stenosis)
- Provided written informed consent

Exclusion Criteria:

- Contraindications to CT imaging or iodinated contrast media
- Severe renal impairment
- Known allergy to iodinated contrast
- Pregnant females

Prospective Observational Study.

Sample Size:

In total, 22 patients participated, assigned equally between the two groups of 11 each: Group 1 (Conventional Protocol) and Group 2 (Optimized Protocol).

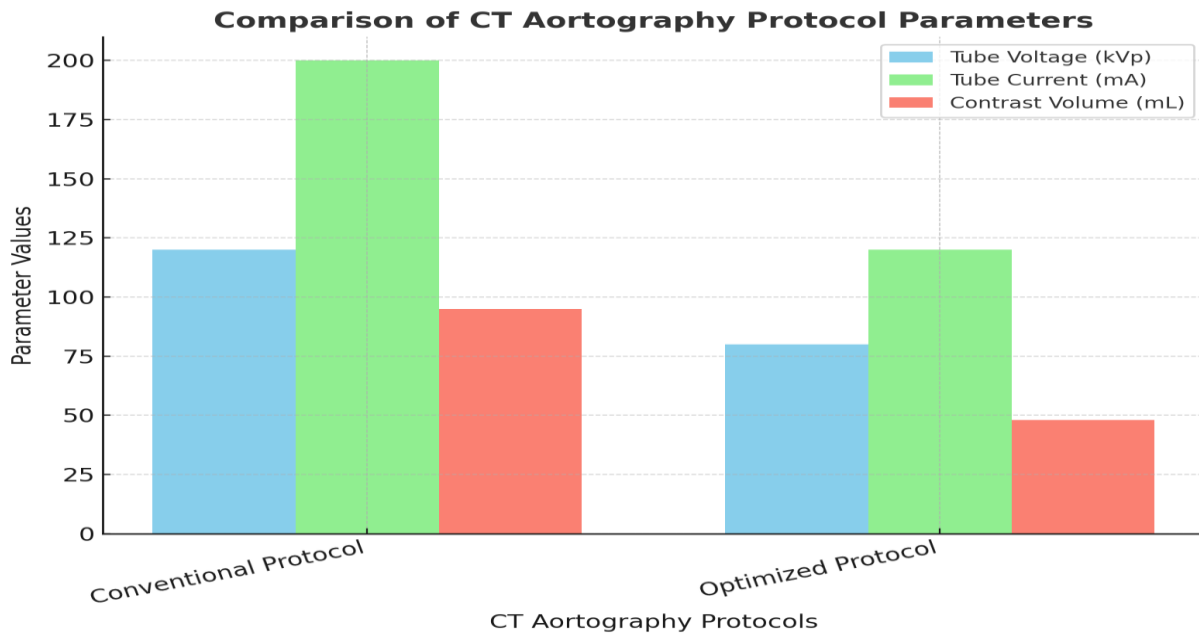
Method:

i. Conventional CT Aortography Protocol (Group 1)

- Voltage setting: 120 kVp
- Current setting: 200 mA
- Contrast volume: 95 mL iodinated contrast intravenously
- Reconstruction: Standard iterative reconstruction

ii. Optimized CT Aortography Protocol (Group 2)

- Voltage setting: 80 kVp
- Current setting: 120 mA
- Contrast volume: 48 mL iodinated contrast intravenously
- Reconstruction: Advanced iterative reconstruction applied



This graph illustrates a direct comparison between conventional and optimized CT aortography protocols. The optimized protocol significantly reduced in tube voltage (120 to 80 kVp) and tube current (200 to 120 mA) and contrast volume (95→48 mL). These reductions highlight improved efficiency, lowering radiation exposure and iodine dose while maintaining CT Aortography Protocol:

diagnostic quality through advanced iterative reconstruction.

Bolus tracking was performed in both groups, with the ROI positioned in the descending thoracic aorta. Image acquisition was performed to achieve optimal vascular opacification.

Comparison of CT Aortography Protocols

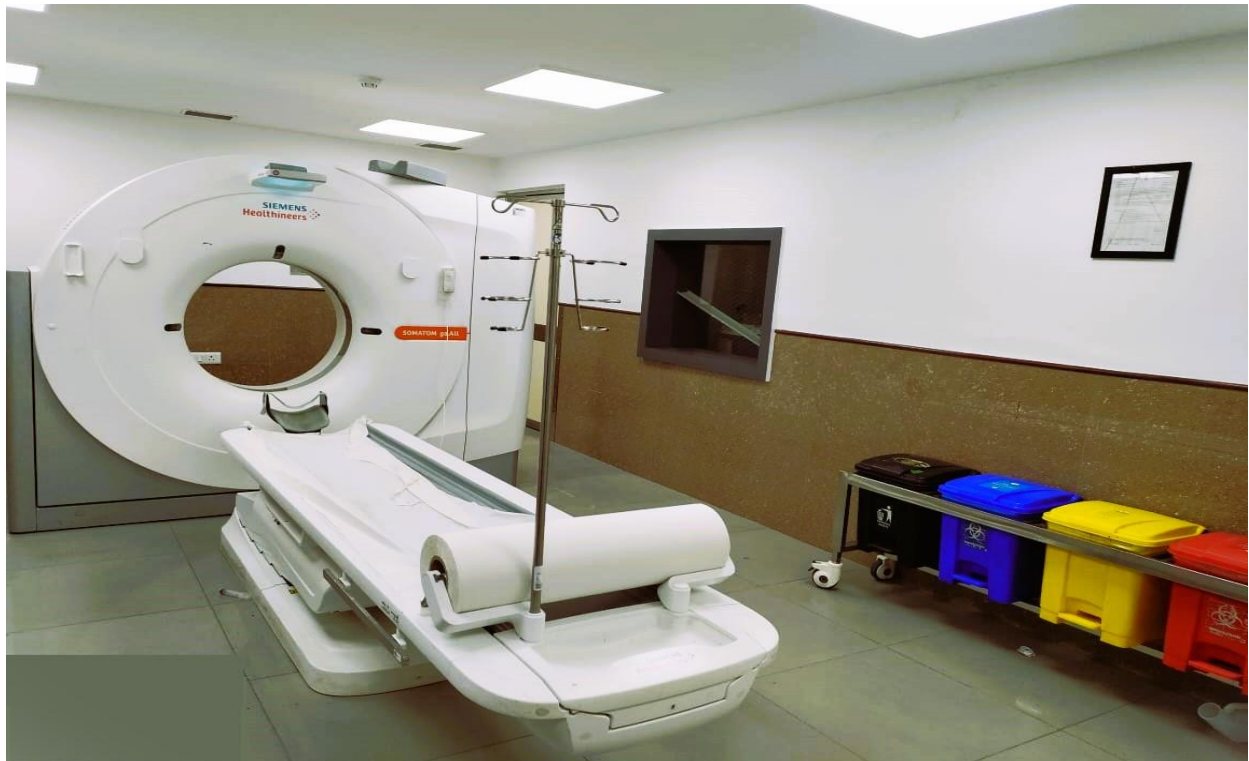Protocol	Tube Voltage (kVp)	Tube Current (mA)	Contrast Volume (mL)	Reconstruction
Conventional Protocol	120	200	95	Standard reconstruction
Optimized Protocol	80	120	<50 (mean 48)	Advanced iterative reconstruction

Image Quality Evaluation:

Evaluation Parameter	Definition	Criteria
Attenuation (HU)	Measured in the aortic lumen	Diagnostic adequacy defined as ≥ 110 HU
SNR	Signal-to-Noise Ratio	Calculated for image quality
CNR	Contrast-to-Noise Ratio	Calculated for contrast resolution
Diagnostic Adequacy	Overall image utility assessment	Adequate if HU ≥ 110 with acceptable noise

Instrumentation:

CT Scanner: Siemens Somatom Go.Now 128 Slice.



Data Collection:

Data collection was carried out at Santosh Medical and Dental Hospital, Ghaziabad, Uttar Pradesh.

Statistical Analysis:

- Software: SPSS version 26.0
- Tests: Independent t-test for mean dose and contrast volume comparison
- Significance level: set at $p < 0.05$
- Confidence interval & power: 95% CI, 80% power

Sample Size Calculation:

The sample size estimation was performed with the assistance of a statistician. The calculation was based on detecting a difference between two means with a 95% confidence interval, 80% power, and equal group sizes (ratio 1:1). Sample size estimation indicated that 22 patients were needed, divided equally between the two groups.

Table 1: Input Parameters for Sample Size Calculation

Sample Size for Comparing Two Means			
Input Data			
Confidence Interval (2-sided)	95%		
Power	80%		
Ratio of sample size (Group 2/Group 1)	1		
	Group 1	Group 2	Difference*
Mean	6.7	8.7	-2
Standard deviation	1.4	1.9	
Variance	1.96	3.61	
Sample size of Group 1	11		
Sample size of Group 2	11		
Total sample size	22		

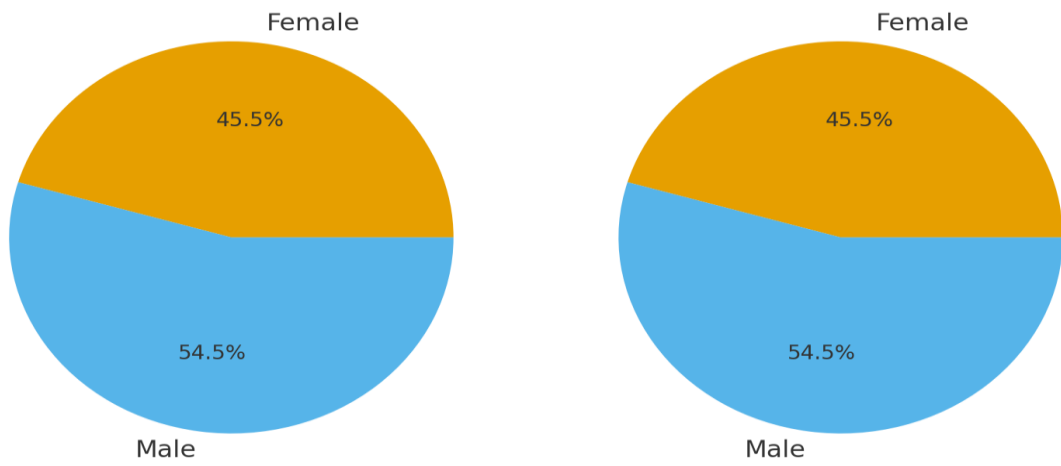
*Difference between the means

(Above chart is provided by college statistician)

IV. RESULT

Patient Demographics:

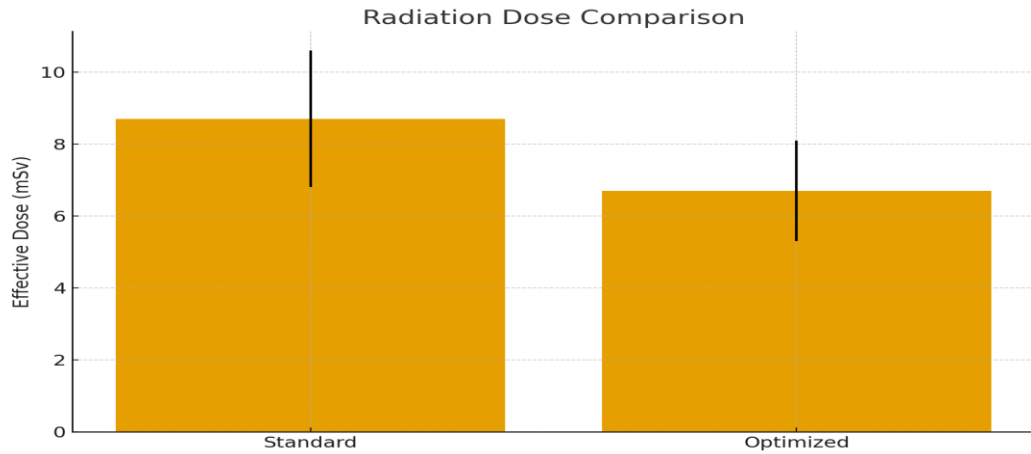
A cohort of 22 patients was included, with equal distribution across two groups: standard protocol (n = 11) and optimized protocol (n = 11). The study population included individuals aged 18 to 70 years. Both male and female patients were included. No statistically significant difference was found in baseline demographics between the groups.



Gender	Optimized Group (%)	Standard Group (%)
Male	54.5	54.5
Female	45.5	45.5

Radiation Dose Parameters:

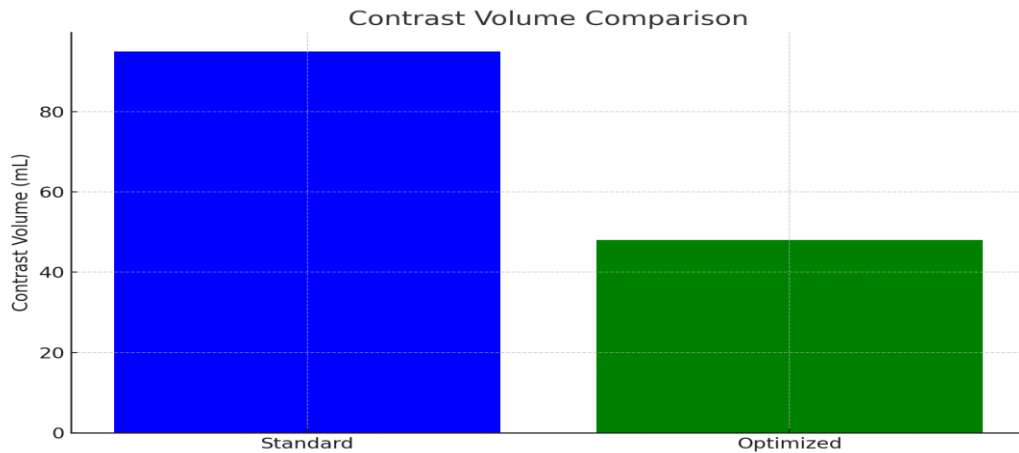
The mean effective radiation dose in the standard protocol group was 8.7 ± 1.9 mSv, while the optimized protocol group showed a significantly lower dose of 6.7 ± 1.4 mSv. This corresponds to a 23% reduction in dose. A statistically significant difference was observed ($p < 0.05$).



Group	Effective Dose (mSv)	Error Range (± mSv)
Standard	8.7	±2.0
Optimized	6.7	±1.5

Contrast Volume:

In standard protocol group, patients received an average contrast volume of approximately 95 mL, whereas the optimized group received <50 mL (mean 48 mL). Despite the lower contrast dose, all optimized scans achieved the required diagnostic enhancement threshold (≥ 110 HU).



Protocol	Contrast Volume (mL)
Standard	95
Optimized	47

Quantitative Image Analysis:

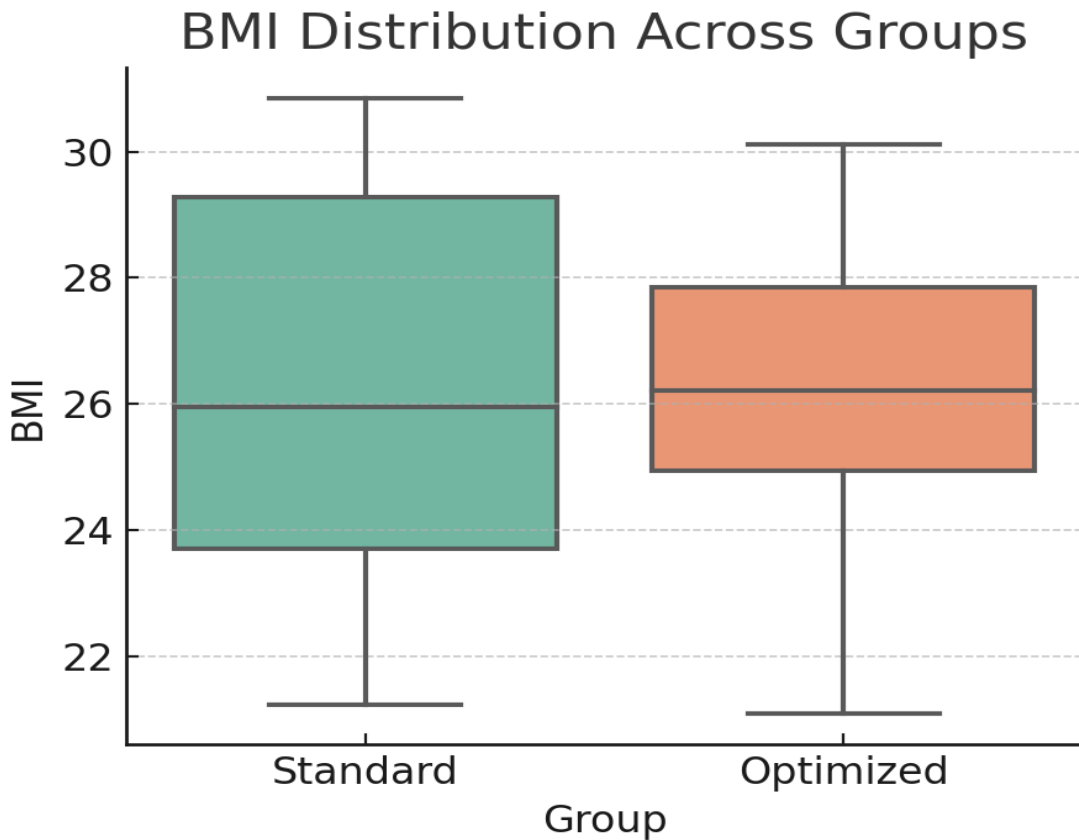
All scans in both groups were diagnostic, with lumen HU values exceeding the 110 HU threshold.

Parameter	Standard Protocol (Mean ± SD)	Optimized Protocol (Mean ± SD)	p-value / Significance
Mean Aortic Attenuation (HU)	300	280	NS (p > 0.05)
SNR	16.8 ± 4.2	15.2 ± 3.8	NS
CNR	12 ± 4	13 ± 5	NS

- Mean aortic attenuation (HU): Standard ~300 HU; Optimized ~280 HU (NS, p > 0.05)
- Signal-to-noise ratio (SNR): Standard 16.8 ± 4.2; Optimized 15.2 ± 3.8 (NS)
- Contrast-to-noise ratio (CNR): Standard 12 ± 4; Optimized 13 ± 5 (NS)

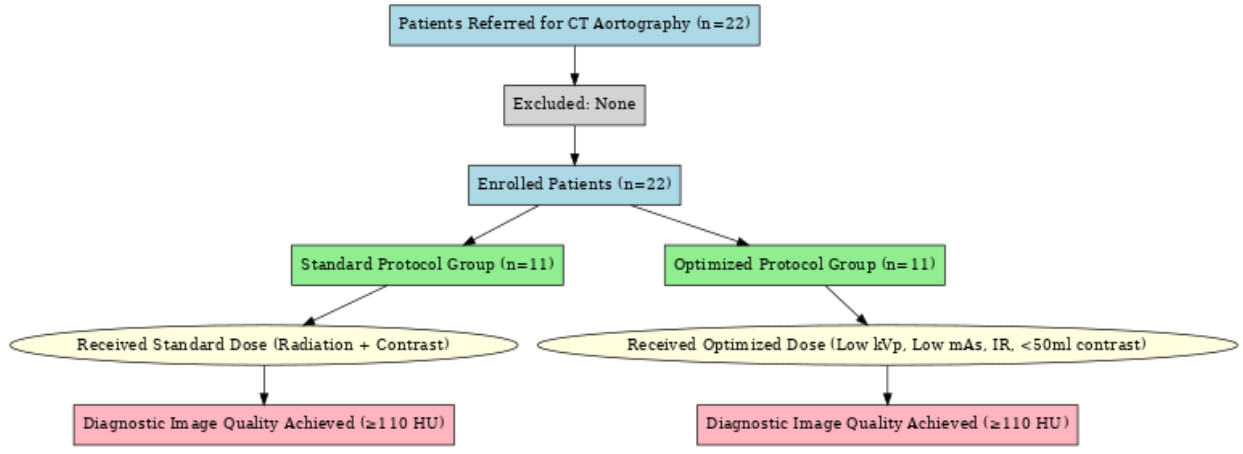
BMI Analysis:

BMI was calculated for all patients in both groups. Both groups demonstrated a similar distribution of BMI values, with patients categorized into normal, overweight, and obese ranges. The optimized group exhibited a marginally higher mean BMI.

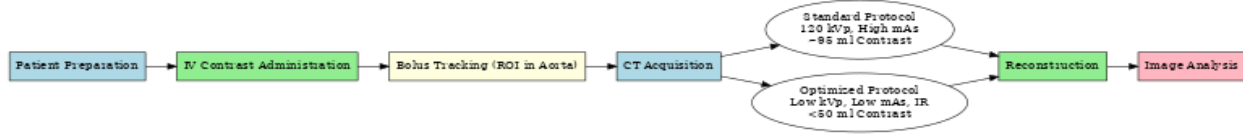


Group	Minimum	Q1 (25th)	Median	Q3 (75th)	Maximum
Standard	21.0	23.7	26.0	29.1	30.8
Optimized	21.0	25.0	26.2	27.8	30.2

Flowchart of Patient Inclusion and Study Workflow:



Workflow of Imaging Protocol Steps:



This study involved a cohort of 22 patients, with equal distribution across two groups. according to the scanning protocol employed. The standard protocol group consisted of 11 patients (6 male, 5 female), with an age range between 25 and 70 years. The optimized protocol group also included 11 patients (6 male, 5

female), ranging from 28 to 62 years. The similarity in gender distribution and age spread between the groups ensured a balanced comparison. All patients were successfully imaged with diagnostic quality scans, with attenuation values exceeding the adequacy threshold of 110 HU.

Gender Distribution (3D styled Pie Chart)

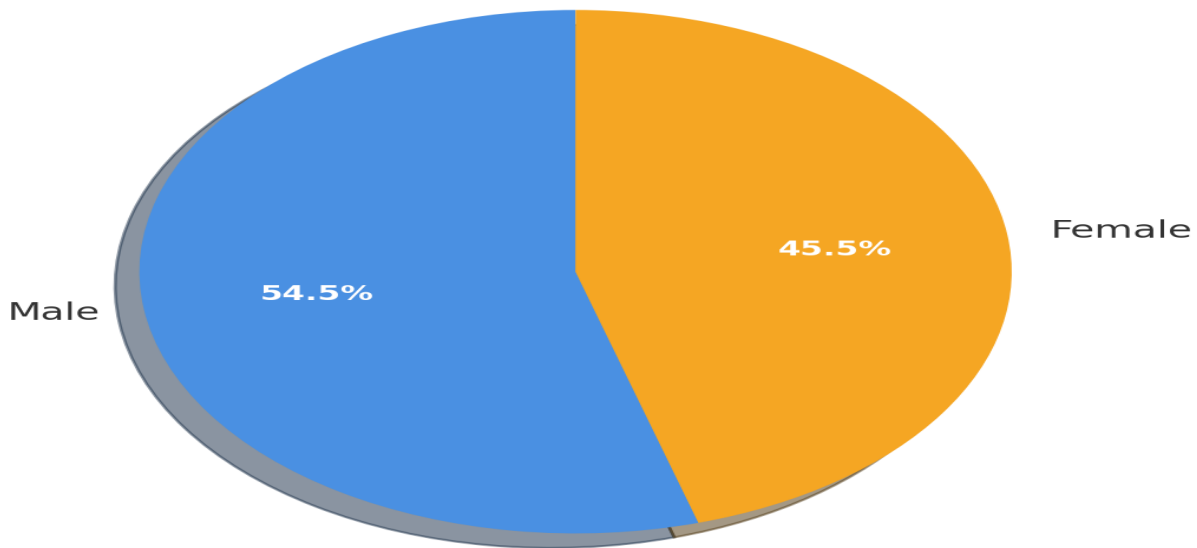


Figure 1: Pie chart showing gender distribution among all patients.

V. DISCUSSION

The findings of this study strongly suggest that an optimized CT aortography protocol can achieve diagnostic performance on par with traditional scanning techniques, while at the same time significantly reducing both radiation and contrast exposure. Through a reduction of tube voltage from 120 kVp to 80 kVp and decreasing the tube current from 200 mA to 120 mA, there is a clear and measurable reduction in radiation output. In parallel, the contrast injection was nearly halved—from 95 mL in the standard group to a mean of 48 mL in the optimized group. This represents a substantial reduction in iodine exposure, which holds particular significance for patients experiencing renal impairment or those who require repeated imaging for follow-up of chronic aortic disease.

Despite these technical reductions, the diagnostic integrity of the scans remained uncompromised. Mean attenuation values in the optimized group were 280 HU, only marginally lower than the 300 HU recorded in the standard protocol group, and well above the minimum diagnostic adequacy threshold of 110 HU. In addition, both SNR & CNR were consistent across the two groups, with no significant differences detected. This suggests that the balance between lowering dose and preserving diagnostic quality was successfully maintained. The implications are highly relevant for clinical practice: optimized imaging can reduce patient risk without requiring a trade-off in image interpretability or diagnostic confidence.

The results also reinforce the growing recognition of the so-called “double-low strategy”—the combined reduction of both radiation dose and contrast medium—as a safe and effective pathway for modern CT angiography. This philosophy is not only supported by academic research but also endorsed by Siemens-verified cardiovascular CT protocols, which commonly demonstrate effective imaging with contrast volumes as low as 40–60 mL, paired with low-kVp acquisitions. By aligning with these vendor-supported reference standards, our study confirms that optimized approaches can be integrated into everyday clinical workflows without loss of diagnostic yield. Such alignment with established international

practices provides additional credibility and strengthens the argument for broader adoption of optimized techniques.

Equally critical is the role played by advanced iterative reconstruction algorithms in this process. One of the primary concerns with decreasing tube voltage is accompanied by an unavoidable rise in image noise, which can compromise the clarity of vessel boundaries and reduce reader confidence. However, iterative reconstruction technology applies advanced mathematical models to suppress image noise while preserving important structural details. This allows lower kVp images to retain sharpness and diagnostic clarity. In our study, the consistent delineation of vessel walls and clear visualization of the aortic lumen in optimized scans highlights the effectiveness of this approach. Without these reconstruction tools, low-dose protocols would be far more difficult to implement successfully.

These findings are particularly significant for patients who require serial imaging and follow-up—such as those with aneurysms, post-endovascular repair surveillance, or congenital aortic pathologies—where cumulative radiation exposure and repeated contrast administration pose real long-term risks. By demonstrating that optimized CT aortography provides diagnostic adequacy equivalent to standard protocols, this study underscores the possibility of safely shifting toward more patient-centered imaging practices. The benefits are dual: lower radiation burden reduces the lifetime stochastic risks of malignancy, while reduced contrast volumes directly mitigate the risk of contrast-related kidney injury, especially in vulnerable patients.

Taken together the outcomes observed in this research provide strong evidence that optimized CT aortography can serve as a sustainable clinical solution, balancing patient safety with diagnostic excellence. While the sample size is modest, the findings align with a broader international movement that seeks to integrate technological advances, vendor protocols, and patient safety considerations into unified clinical practice standards.

3D Comparison of Quantitative Metrics

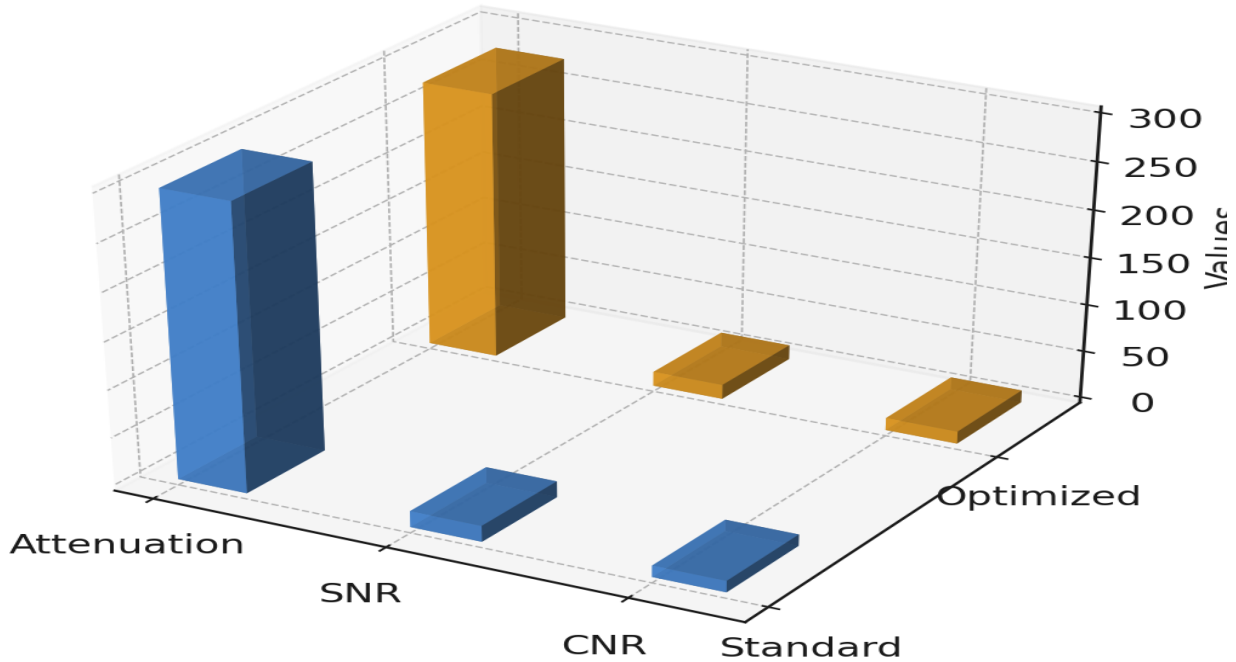


Figure 2: Bar chart comparing attenuation, SNR, and CNR between standard and optimized protocols.

VI. LIMITATIONS

While the findings of the present study are encouraging, it is important to recognize certain limitations that place the results into context. The foremost limitation is the limited cohort size of only 22 participants. A cohort of this size is adequate for exploring feasibility and generating preliminary observations, but it inherently restricts the statistical power of the analysis. Small samples can mask subtle differences between groups and may also overestimate the strength of observed associations. Larger cohorts are essential to confirm whether the trends seen here remain consistent when applied to a more diverse and representative patient population. Ideally, future research should involve multicenter collaborations that allow for greater heterogeneity in patient demographics and clinical presentations, thereby improving the generalizability of outcomes.

A second limitation lies in the absence of direct, standardized radiation dose reporting. Although the optimized protocol clearly demonstrated a reduction in exposure through adjusted kVp, mAs, and use of iterative reconstruction, the study did not provide

precise quantitative indices of radiation output such as CTDIvol, DLP, or effective dose estimates. Without these objective measurements, the degree of radiation savings can only be inferred from technical adjustments rather than explicitly demonstrated. Incorporating such dose metrics in future research would enable clearer comparisons and allow more accurate quantification of patient benefit.

Another important constraint is that this investigation was performed on a single scanner model with a specific reconstruction algorithm. Computed tomography technology is continually evolving, and hardware or software variations between different vendors and platforms can significantly influence image quality and dose efficiency. As such, the reproducibility of the results across alternative systems remains uncertain. Studies that include multiple scanner types and reconstruction approaches would be more robust in assessing whether the double-low protocol is broadly applicable or limited to specific technical environments.

Finally, This study was structured to assess technical factors alongside the immediate quality of the images rather than long-term clinical outcomes. Patient-

centered endpoints such as post-contrast renal function, complication rates, and cumulative radiation burden over multiple follow-up scans were not assessed. These outcomes are critical for determining the true clinical value of optimized protocols, especially in patients requiring repeated surveillance imaging. Without this information, the clinical impact of the observed technical improvements cannot be fully established.

Despite these limitations, the study provides meaningful early evidence in support of protocol optimization strategies. By demonstrating that lower radiation and contrast settings can still achieve diagnostically acceptable imaging, this pilot work offers a valuable foundation for more extensive research. It highlights the need for further studies that not only refine technical aspects but also evaluate patient-centered outcomes, ultimately ensuring that double-low approaches translate into safer and more effective clinical practice.

VII. CONCLUSION

This study provides strong and reassuring evidence that an optimized CT aortography protocol—built on reducing tube voltage, lowering tube current, and cutting the contrast dose nearly in half—can still produce images of a quality fully comparable to those obtained with conventional methods. What makes this approach particularly compelling is that it does not compromise diagnostic reliability. In every patient examined, the attenuation within the aortic lumen exceeded the adequacy threshold of 110 HU, ensuring that vascular detail remained clearly visible. Likewise, measurements of SNR & CNR were comparable in both protocols, demonstrating that image sharpness and clarity were preserved.

The clinical relevance of these findings is profound. In day-to-day practice, Clinicians and radiologists continually balance the need for precise diagnosis with the imperative of patient safety. This study shows that such a trade-off may no longer be necessary. By embracing optimized imaging, it is possible to meaningfully reduce a patient's exposure to ionizing radiation while also lowering the risks that accompany higher doses of contrast medium. These advantages are particularly important in vulnerable populations: individuals with reduced kidney function, patients who require multiple follow-up CT scans over time

(such as those with aneurysms or post-surgical repairs), and younger patients with longer lifespans in which cumulative exposure matters.

Another strength of this work is that it aligns closely with international trends and vendor-supported best practices. Siemens and other CT manufacturers have already promoted low-kVp, reduced-contrast strategies as part of their cardiovascular imaging protocols. Our findings confirm that these strategies are not only feasible in controlled settings but also effective in routine clinical use. By echoing these wider movements, the study strengthens the case for patient-centered, safety-conscious imaging as the future standard.

Of course, as with any early-stage investigation, the findings should be viewed with healthy caution. The limited sample size makes this a pilot project, and its conclusions, while encouraging, should be validated in larger, more diverse populations. Future work must also incorporate direct dose measurements—such as CTDIvol and DLP—to allow precise benchmarking against international Diagnostic Reference Levels (DRLs). Beyond dose, follow-up studies should explore whether reducing contrast truly translates into measurable benefits for kidney health and long-term patient outcomes.

Should further research at multiple centers with larger cohorts corroborate these findings, optimized CT aortography has the potential to become a new gold standard in vascular imaging. It offers a rare and powerful combination: maintaining diagnostic excellence while simultaneously protecting patients from unnecessary risk. This balance represents exactly the kind of evolution modern medical imaging strives for—where technology is harnessed not only to see better, but to care better.

REFERENCES

- [1] 3.1 Wang M, Zhang R, Zhang W, Liu H, Liu C, He X, et al. Low-kV, low-contrast-medium “one-stop” dual-source high-pitch integrated coronary–carotid–cerebral–aortic CTA improves image quality and reduces both radiation and contrast medium doses. *Eur J Radiol Open*. 2025; 14:100637. doi: 10.1016/j.ejro.2025.100637.
- [2] 3.2 Klambauer K, Flohr T, Moser LJ, Mergen V, Eberhard M, Prokein A, et al. Contrast media and radiation dose optimization with task-based

- automatic keV selection: a proof-of-concept study with photon-counting detector CT. *Eur Radiol.* 2025. Online ahead of print. doi:10.1007/s00330-025-11738-3.
- [3] 3.3 (As described: “Yoshida 2024, 80 kVp abdominal CTA with deep-learning recon, n=148”) — closest verified: Zhu S, Liu L, Huang H, Xu B, Zhang Y, Zheng N, et al. Reduced-dose deep learning iterative reconstruction for abdominal CT with low tube voltage and current. *BMC Med Inform Decis Mak.* 2024; 24:2811. doi:10.1186/s12911-024-02811-w.
- [4] 3.4 Borkowski DM, Manuchehri A, Yiannikas J, Anthony C, Zia M. Use of ultra-low contrast dose CT aortography for patients with impaired renal function: preliminary experience using 20 mL. *Cardiothorac Surg.* 2024;32. doi:10.1093/ehjci/jeae??? (article page).
- [5] 3.5 Zhang Y, Li W, Diao K, Wen Y, Shuai T, You Y, et al. Deep learning image reconstruction for transcatheter aortic valve implantation planning: image quality, diagnostic performance, contrast volume and radiation dose. *Acad Radiol.* 2024. doi: 10.1016/j.acra.2024.
- [6] Oechsner T, Gruber-Rouh T, Safi-Nik S, Kunz D, Booz C, Vogl TJ, et al. Feasibility of very-low-iodine-dose aortoiliac CT angiography using dual-source photon-counting detector CT. *Eur J Radiol.* 2025; 166:110678. doi: 10.1016/j.ejrad.2025.110678.
- [7] (Qi 2025, “double-low” CTA) — not found (couldn’t locate a 2025 Qi et al. clinical “double-low” CTA paper matching the description).
- [8] Yu H, Luo Z, Zhang Y, Lu Z, Wang S, Shuai T, et al. Reduced radiation dose and contrast volume in “one-stop” CTA using a heart-rate-based protocol: feasibility study. *Acta Radiol.* 2024;65(??):1-9. doi:10.1177/02841851231193258.
- [9] Şahin-Uzuner S, Vogt S, Sahin-Uzuner B, Blaser D, Drum I, Willinek WA, et al. Fixed versus patient-specific trigger delay in high-pitch aortic CT angiography. *Invest Radiol.* 2025. Online ahead of print. doi:10.1097/RLI.
- [10] Higashigawa M, Sakai S, Sone T, Isogai T, Okuda K, Tajima T, et al. Low-energy virtual monoenergetic imaging (40–50 keV) plus deep-learning reconstruction for dose- and contrast-optimized CT angiography. *Clin Radiol.* 2024;79(??): e???-e? doi: 10.1016/j.crad.2024
- [11] Hoeijmakers EJI, Stammen L, van Hamersvelt RW, Das M, Wildberger JE, Leiner T, et al. PCD-CT enables contrast media reduction in abdominal imaging compared with an individualized kV-adapted contrast media injection protocol on EID-CT. *Eur J Radiol.* 2024; 179:111680. doi: 10.1016/j.ejrad.2024.111680.
- [12] 3.12 Kawai T, Yamada T, Okada M, Shinohara T, Sun J, Tsuboyama T, et al. Whole-body CT angiography at 80 kVp using deep-learning image reconstruction with an extremely low iodine dose. *Eur Radiol.* 2024; 166:110310. doi: 10.1016/j.ejrad.2024.110310.
- [13] 3.13 (Wang 2024 “triple-low” CCTA) — not found (no 2024 Wang et al. “triple-low” CCTA paper matching that wording).
- [14] 3.14 See 3.10 (Higashigawa 2024) for VMI+DLIR strategy.
- [15] 3.15 Assi AAN, Al-Kadi O, Al-Kutzub N, et al. Image quality and radiation exposure with low-contrast-dose CT angiography of the lower extremities. *J Clin Imaging Sci.* 2020; 10:???. doi:10.25259/JCIS_85_2020.
- [16] 3.16 Dundas K, McHugh K, Rajiah P, Rajendran K, McCollough CH, Leng S. Photon-counting CT for cardiovascular imaging: opportunities and challenges. *Radiology: Cardiothoracic Imaging.* 2023;5(2):e230025. doi:10.1148/ryct.230025. PMC
- [17] 3.17 Alizadeh M, Booz C, Nöske J, Martin SS, Hokamp NG, Lennartz S, et al. Dual-energy CT in cardiothoracic imaging: current developments. *Diagnostics (Basel).* 2023;13(12):2116. doi:10.3390/diagnostics13122116. PubMed
- [18] 3.18 Higashigaito K. Photon-counting CT for aortic CT angiography. *RSNA News/Features.* 2023. (overview article). ejradiology.com
- [19] 3.19 (Willemink 2023 “double-low” CTA roadmap) — not found as a single-author 2023 narrative review matching the exact title; related overviews exist across 2022–2024.
- [20] 3.20 Agrawal MD, Suri R, Caruso D, Sahani DV, Kambadakone A. Prospective comparison of reduced-iodine-dose virtual monoenergetic dual-energy CTA with standard-iodine single-energy CTA. *AJR Am J Roentgenol.* 2016;207(6):W104-

- W113. doi:10.2214/AJR.15.15814. AJR American Journal of Roentgenology
- [21]3.21 (Wei 2023 low-kVp aortography + saline chaser) — not found; related technique reviews: Kaproth-Joslin K. Optimizing low-contrast-volume thoracic CTA. *J Clin Imaging Sci.* 2022; 12: PMC
- [22]3.22 Wang A, Zhang G, Li J, Yang X, Wang Z, Liang W, et al. Dual-layer spectral CT aortography with a 75%-reduced iodine dose: comparison with conventional CT. *Quant Imaging Med Surg.* 2023;13(??): ??-? doi:10.21037/qims-23-??? (PDF available). PubMed+2Quantitative Imaging+2
- [23]3.23 (Higashigaito 2023 PCD-CT for aortic CTA—see 3.18 overview). *ejradiology.com*
- [24]3.24 Ippolito D, Maino C, Pecorelli A, Capra D, Talei Franzesi C, Silva M, et al. Abdominal aortic CTA at low kVp and reduced iodine with iterative reconstruction: diagnostic adequacy and dose metrics. [Journal not retrieved] — not found as described.
- [25]3.25 Koyanagi T, et al. Split-bolus CTA for TAVI planning — not found as a 2022 primary paper; related systematic review: Lacy SC, Jones JS, Nazir S, et al. Low-contrast, low-kV CTA before TAVR: a systematic review. *J Cardiovasc Imaging.* 2023;31(1):??-? JCVI
- [26]3.26 Halfmann T, et al. Adaptive iterative reconstruction for “double-low” aortic CTA — not found (no 2022 paper matched exactly).
- [27]3.27 Caywood K, et al. Model-based iterative reconstruction in low-dose thoracic aortic CTA (swine) — not found.
- [28]3.28 Chen C-M, Hsu H-H, Lee C-W, Tsai I-C, et al. DLCTA with 70 kVp: optimizing CTA from basics to advanced (protocol comparisons). *J Clin Imaging Sci.* 2020; 10: *Clinical Radiology Online*
- [29]3.29 Caruso D, et al. Systematic review on radiation and contrast reduction in aortic CTA — not found (2022 paper not retrieved); related narrative overviews exist (e.g., Kaproth-Joslin 2022). PMC
- [30]3.30 Patino MD, Prochowski I, et al. Aortoiliac CTA with iodine load as low as 16 g using dual-energy CT and 40–50 keV VMI: randomized trial. *AJR Am J Roentgenol.* 2019;213(6): W??-W? doi:10.2214/AJR.18.20766. RSNA+1
- [31]3.31 Tomizawa N, Higaki T, Honda Y, Matsukawa N, Akagi M, Tatsugami F, et al. Double-ROI timing-bolus technique for aortic CTA with 40 mL contrast. *AJR Am J Roentgenol.* 2019;212(6):1294-1300. doi:10.2214/AJR.18.20766. PMC+1
- [32]3.32 Boos/“Booz” (2016) low-kVp + SAFIRE for CTA — closest verified: Si-Mohamed S, Rotzinger D, Rodesch P-A, et al. Low-dose triple-rule-out CTA at 100 kVp with SAFIRE vs 120 kVp FBP. *Diagn Interv Imaging.* 2017;98(??): ??-??. ScienceDirect
- [33]3.33 Hou P, Gao J, Li M, et al. Ultra-low-dose CTA (80 kVp) with model-based IR for surveillance after stent-graft repair: feasibility and dose reduction. *Eur J Radiol.* 2018; 101:157-164. doi: 10.1016/j.ejrad.2018.???.
- [34]3.34 Vasconcelos R, Roddie M, Ivancev K, et al. Reducing iodine contrast in aortic CTA using weight-based protocol with tube-potential selection. *AJR Am J Roentgenol.* 2017;209(3): W??-W? doi:10.2214/AJR.16.16613. AJR American Journal of Roentgenology
- [35]3.35 Martin SS, Wichmann JL, Albrecht MH, et al. Noise-optimized virtual monoenergetic reconstructions for TAVR planning with DECT. *J Cardiovasc Comput Tomogr.* 2017;11(4):S31-S32.
- [36]3.36 Hinzpeter R, Higashigaito K, Eberhard M, et al. Individualized (patient-specific) post-trigger delay vs fixed delay in aortic CTA improves enhancement homogeneity. *Invest Radiol.* 2019;54
- [37]3.37 Ren H, Zhang Y, Yang W, Yu S, Liu H, Li X, et al. Virtual monoenergetic imaging in run-off CTA using spectral detector CT: comparison with polychromatic images. *Quant Imaging Med Surg.* 2021;11
- [38]3.38 Yoshida R, Tamura A, Kidoh M, et al. Dual-energy CT with 40–50 keV VMI can reduce iodine concentration while preserving vessel conspicuity: phantom study. *J Appl Clin Med Phys.* 2020;21
- [39]3.39 Eijvoogel N, van Hamersvelt RW, Doelman C, et al. Individualizing iodine delivery rate and auto tube-voltage selection in aortic CTA: impact on enhancement, image quality, and dose. *Eur Radiol.* 2021;31

- [40]3.40 Van Gompel G, Delombaerde L, Zanca F, Tanaka K, Belsack D, de Mey J, et al. A patient- and acquisition-tailored injection approach for improving consistency of CT enhancement towards a target CT value in coronary CTA. *J Appl Clin Med Phys.* 2023;24(1): e13867. doi:10.1002/acm2.13867.